

# DEMYSTIFYING SCOLIOSIS: GET THE LOW- DOWN ON ASSESSMENT AND TREATMENT

COMBINED SECTIONS MEETING 2017  
SAN ANTONIO, TEXAS FEBRUARY 15-18


**Christine Lynders PT, OCS**

Demystifying Scoliosis Feb 18, 2017  
Property of Christine Lynders, Not to be distributed without permission

## LEARNING OBJECTIVES

- 1. Identify the nature of a scoliotic curve and the specific muscles which have shortened and lengthened
- 2. Describe how a scoliotic curve can have a direct effect on neck and back pain, including radiculopathy
- 3. Execute an appropriate evaluation to determine the influence the scoliosis is having on their pain
- 4. Apply specific manual therapy techniques and 3D therapeutic exercises to improve spinal mobility and function

Demystifying Scoliosis Feb 18, 2017  
Property of Christine Lynders, Not to be distributed without permission



## OUTLINE

- Welcome and introduction
- Relevant anatomy and biomechanics for type I and type II scoliotic curves
- Identify the curve and determine which muscles need to be lengthened and which need to be strengthened
- Spinal evaluation and differential diagnosis
- Case study presentations (2)

Demystifying Scoliosis Feb 18, 2017  
Property of Christine Lynders, Not to be distributed without permission

INSPIRATION  
FOR THIS  
TALK  
Why Scoliosis?



Demystifying Scoliosis Feb 18, 2017  
Property of Christine Lynders, Not to be distributed without permission

## WHAT IS SCOLIOSIS ?

- A 3-dimensional curvature of the spine that causes a variety of asymmetries and muscular imbalances (compensations) throughout the body over time
- Idiopathic Scoliosis: "a torsional deformity of the spine, which combines a translation and rotation of a variable number of vertebrae, changing the 3D geometry of the spine." (Negrini, 2012)

Demystifying Scoliosis Feb 18, 2017  
Property of Christine Lynders, Not to be distributed without permission

## CAN I GET SCOLIOSIS?



Demystifying Scoliosis Feb 18, 2017  
Property of Christine Lynders, Not to be distributed without permission

## SPINAL BIOMECHANICS

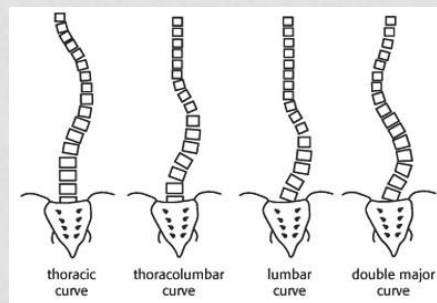
- **Type I (Idiopathic)** – Sidebending and rotation of the spine occur in **opposite** directions in neutral
- **Type II (Compensatory)**– In non-neutral (in flexion or extension when the spine is engaged), sidebending and rotation couple toward the **same** side
- **Scoliosis** -A structural spinal curvature with Cobb angle  $> 10^\circ$  AND axial rotation where the curve is present regardless of position

## BART...THE LIZARD, THE MYTH, THE LEGEND



Demystifying Scoliosis Feb 18, 2017  
Property of Christine Lynders, Not to be distributed without permission

## CURVE TYPES



- There's many different types of curves one can develop.

Scoliosisbackpain.com

Demystifying Scoliosis Feb 18, 2017  
Property of Christine Lynders, Not to be distributed without permission

## WHO GETS SCOLIOSIS?

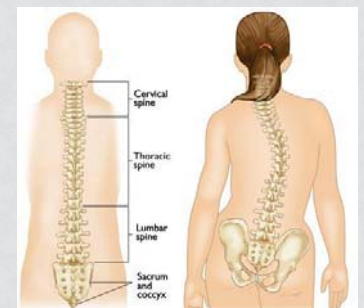
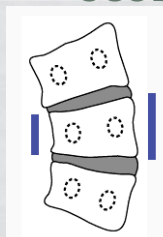


- Different Types:
  - **Idiopathic**
    - Pediatric/infants
    - Adolescent growth spurt ages 10-18
  - **Functional**
    - Arising from a non-spinal underlying cause such as LLD, prolonged abnormal posture, or muscle spasm. Correctable if underlying cause is addressed.
  - **Degenerative**
    - Adults from collapsing vertebrae, DDD, spondylolisthesis, osteoporosis (NOT progressive AIS)
    - Teens from slouching on sofa playing video games??
  - **Iguanas?!!**

Demystifying Scoliosis Feb 18, 2017  
Property of Christine Lynders, Not to be distributed without permission

## PATHOMORPHOLOGY & PATHOMECHANICS OF IDIOPATHIC SCOLIOSIS?

- Vertebral wedging (actual wedging)
- 3D curvature through growth spurt, involving rotational component

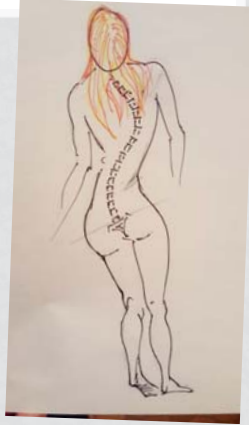

StudyBlue.com

Demystifying Scoliosis Feb 18, 2017  
Property of Christine Lynders, Not to be distributed without permission

## AFFECTS ON THE BODY

- Rib hump, scapular winging
- Pelvic compensation
- LLD compensation
- Ankle/Foot compensation (pronation/supination)
- Shoulder heights uneven
- Head compensation



- **2011 SOSORT guidelines**

Demystifying Scoliosis Feb 18, 2017  
Property of Christine Lynders, Not to be distributed without permission

## RESULTS??

- **As the brain tries to compensate for the asymmetry, we get altered movement patterns, muscle guarding and muscle inhibition.**

## PROBLEMS IN THE ADULT WITH H/O SCOLIOSIS

1. Facet joint degeneration leading to nerve impingement on side on compression/concavity (stenosis)
  - Chronic hip drop (Gluteus medius instability) → repetitive sidebending
  - Hip OA
  - Runner (with trendel...)
2. Disc herniations from repetitive shear/rotation during ADLs
3. Hip pain, OA, bursitis; Knee pain from wear and tear with excess femoral IR
4. *Neck and peri-scapular pain from scapular muscle imbalance and poor positioning on the thorax*

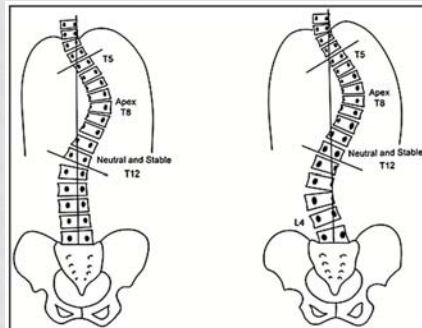
Demystifying Scoliosis Feb 18, 2017  
Property of Christine Lynders, Not to be distributed without permission

## TRY THIS!!

- How are you sitting right now? Close your eyes. Equal weight on ITs? If so, great! If not, what message are you sending your brain? What position is your spine in? SB one way or other?? Now sit that like for 10 years and see what happens
- Straighten yourself up and close your eyes. How does it feel?
- Bend your self sideways and close your eyes. How does it feel. Now see if, with your eyes closed, you can correct yourself.

## AS THE SCOLIOSIS AGES...

- The muscles on the concave side continue to shorten as they remain in the shortened position
- The muscles on the convex side continue to be lengthened/strained causing a progression of the already dysfunctional curve
- Vertebral bodies wedge/collapse, discs herniate and canals narrow = **PAIN!!**



Demystifying Scoliosis Feb 18, 2017  
Property of Christine Lynders, Not to be distributed without permission

## WHAT IS OUR GOAL?

- **Halt the curve progression!** (and restore previous curve?)
- **Decrease pain and disability**
- **Optimize function**
  - Restore normal movement/minimize abnormal patterns)
  - Re-train the nervous system
- **Restore ability to safely return to enjoying their desired life activities/hobbies without re-aggravation of their symptoms**

## WHERE DO WE START?

- **Understand their curve** : Thorough Evaluation
- **Understand what activities they would love to continue** or get back to doing to enjoy life to their best ability
- **Educate them** so THEY understand their curve and **what positions/activities aggravate**, correct
- **Teach them** what postures during their everyday life that can be creating strain and educate them **how to correct those positions**
- THEY need to understand **the importance of their role** in this!!
- **EMPOWER THEM.**      **INSPIRE THEM**

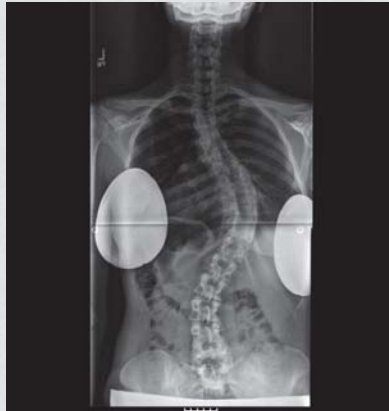
## GOOD NEWS...WHO CAN WE HELP???

- **All of the above!!**
- Today our focus will be on the young and older adult with history of idiopathic scoliosis who have developed compensatory neck or back pain.

Demystifying Scoliosis Feb 18, 2017  
Property of Christine Lynders, Not to be distributed without permission

## IMAGING: IDIOPATHIC SCOLIOSIS

- EF, Braced as a child with corset
- Curve **60°** 2010  
\*\*Reports curve was **48°** 10yrs prior
- Failed Schroth 2 yrs ago
- T9 apex curve = 38°
- L3 apex curve = 22°
- C/o L low back pain, **R neck**, upper shoulder; wakes with HA due to neck pain (pain resolved while on

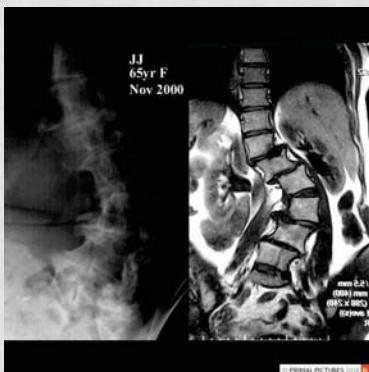

## WHAT TREATMENT IS AVAILABLE?

- **Early bracing**
  - Types
    - Boston, Milwaukee, Providence (over-correction nighttime brace), Charleston (over-correction nighttime brace )
    - Rigo-Cheneau, Cheneau, Sforzesco, DDB Spondylos
- **\*Physical Therapy Intervention**
  - Traditional
  - Schroth
- **Surgery**

Demystifying Scoliosis Feb 18, 2017  
Property of Christine Lynders, Not to be distributed without permission

## IMAGING: DEGENERATIVE SCOLIOSIS



Demystifying Scoliosis Feb 18, 2017  
Property of Christine Lynders, Not to be distributed without permission

## BRACING IS IMPORTANT

### Bracing

- BRAIST Study 2013, Weinstein, et al- use of brace 18 hours a day significantly decreased high risk curve progression to the threshold of surgery AND found a significant relationship between wear time and likelihood of brace success

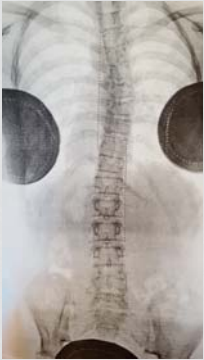

Demystifying Scoliosis Feb 18, 2017  
Property of Christine Lynders, Not to be distributed without permission

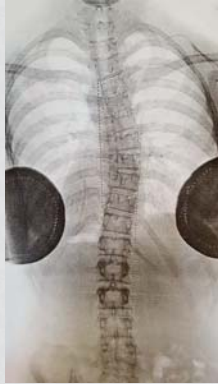
Higgy Bear Pinterest

## BRACING ADOLESCENT PROGRESSION

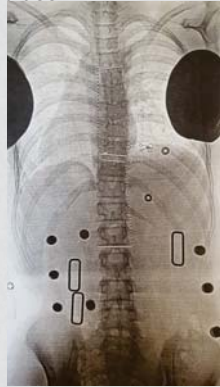
3/30: 15R, 28L



11 /29: 17R, 33L



6/15: Prone in brace



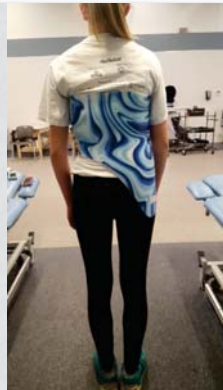Demystifying Scoliosis Feb 18, 2017  
Property of Christine Lynders, Not to be distributed without permission

## SCHROTH EVIDENCE

- Schreiber, S et al 2015. Curve Cobb angle decreased!!!
- SOSORT : International Society on Scoliosis Orthopaedic and Rehabilitation treatment
- Ethical Concerns

Demystifying Scoliosis Feb 18, 2017  
Property of Christine Lynders, Not to be distributed without permission

## BRACING



Demystifying Scoliosis Feb 18, 2017  
Property of Christine Lynders, Not to be distributed without permission

## SCHROTH RESOURCES

- [www.scoliosiseducationseminars.com](http://www.scoliosiseducationseminars.com)
- Marissa Muccio

Demystifying Scoliosis Feb 18, 2017  
Property of Christine Lynders, Not to be distributed without permission

## SCHROTH

- Origin of Schroth: Katharina Schroth 1920s Germany
- Primary focus on correcting rotational component to improve breathing and then integrate auto-correction in front plane
- Barcelona School
- **Intensive 60 min, 5 days a week for several weeks** (20 hours is recommended to become independent in auto-correction HEP)

Demystifying Scoliosis Feb 18, 2017  
Property of Christine Lynders, Not to be distributed without permission

## EVIDENCE FOR MANUAL THERAPY AND EXERCISE

- SEAS study:, Negrini et al. 24 Dec 2014.
- Conclusions- SEAS is an approach to scoliosis exercise treatment with a strong modern neurophysiological basis, to reduce PT requirement and possible costs for families linked to frequency of treatments and evaluations.

Demystifying Scoliosis Feb 18, 2017  
Property of Christine Lynders, Not to be distributed without permission

## EVIDENCE FOR MANUAL THERAPY AND EXERCISE

- Scoliosis Research Society (SRS) reported that "AAOS, SRS, POSNA and AAP believe that recent high quality studies demonstrate that non-operative interventions such as bracing and scoliosis specific exercises can decrease the likelihood of the curve progression to the point of requiring surgical treatment."
- (<http://www.srs.org/about-srs/quality-and-safety/position-statements/screening-for-the-early-detection-for-idiopathic-scoliosis-in-adolescents>)

Demystifying Scoliosis Feb 18, 2017  
Property of Christine Lynders, Not to  
be distributed without permission

## MY APPROACH

- **GET TO KNOW THE CURVE!!!** Draw it out.
- Look at Xrays.
- Find out their habits, sports, hobbies, functional limits.
- **Learn what compensations their body has made overtime in the face of the curve.** Watch them walk. Look at how they move to see what muscle firing patterns are off.

Demystifying Scoliosis Feb 18, 2017  
Property of Christine Lynders, Not to  
be distributed without permission

## EVIDENCE FOR MANUAL THERAPY AND EXERCISE

- **Negrini et al: Dec 2008**
- 5 year study of 25 y/o female. Treatment of curve decreased from 46° to 37° at 19 y/o.
- Increased Cobb angle 10° over 6 years.
- Used scoliosis specific exercises with 30 min every day at home x 1 year.
- **Curve reversed from 47° to 28.5°!**
- Conclusions: When adult scoliosis progresses, it is possible to intervene with exercises to not only gain stability, but to recover last year's collapse.
- The decrease in curve does NOT indicate reduction of the bony deformity but **recovery of the upright postural collapse**, which can decrease the chronic asymmetrical load on the spine and in the long run, reduce risk of progression.

- **Scoliosis Journal**

Demystifying Scoliosis Feb 18, 2017  
Property of Christine Lynders, Not to  
be distributed without permission

## BREAKDOWN....

- **Thought process**
  - What can I do to alleviate the scoliotic progression so she won't have continued on/off pain
  - What sort of HEP can I teach her to do on her own to continue to maintain the gains???
- **Basic Principles**
  - Know the curve.
  - Short muscles one side, long muscles opposite side
  - How can I effect a change?
    - Release the short side and re-educate/strengthen the long side?!
- On HEP: it takes thousands of reps for an athlete to develop a motor plan so that it becomes automatic. The same applies here. They need to address their postural habits and learn a new way to move, sit etc. in a corrected way until their brain forms new pathways and adopts this as normal

Demystifying Scoliosis Feb 18, 2017  
Property of Christine Lynders, Not to  
be distributed without permission

Before PT



AFTER PT



Demystifying Scoliosis Feb 18, 2017  
Property of Christine Lynders, Not to  
be distributed without permission

## CASE STUDY

- 30 y/o female interior designer with congenital scoliosis diagnosed in 8<sup>th</sup> grade with 43 °curve. Used a corrective brace for 2 years. Used to be a dancer
- **Diagnosis:** Thoraco-Lumbar Scoliosis , HNP L4-5, L5-S1
- **Functional Complaints** – L lumbar, gluteal, calf “sciatica,” R anterior hip pain & R upper shoulder pain to walk >5 minutes on commute, to stand longer than 10 minutes and to sit >1hour at work.
- Repeated “flare-ups” pain every 2 years and multiple bouts of PT which abated symptoms briefly, but not permanently.
- **Patient Goals:** To come up with an exercise routine that she can do to decrease her every day pain and prevent recurrent flare-ups

## IMAGING

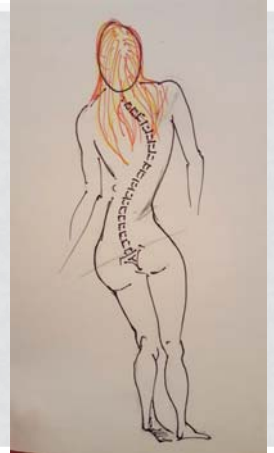- Xrays in the last year
- Medications:  
Methylprednisone  
for one more day
- Skelaxin and  
Tramadol as  
needed



Demystifying Scoliosis Feb 18, 2017  
Property of Christine Lynders. Not to  
be distributed without permission

## Evaluation Findings

- **Curve:**  
Thoracic spine: R Rot, L SB  
Lumbar: L Rot, R SB
- **Strength:** hip abd R 5/5. L 4/5
- **Palpation:** Tenderness at L  
gluteus medius, piriformis, R  
upper trapezius with  
hypertonicity, R lumbar spine  
multifidii, L thoracic spine  
multifidii, R hip flexor tendons  
and inguinal ligament



## Subjective Complaints and Functional Limitations

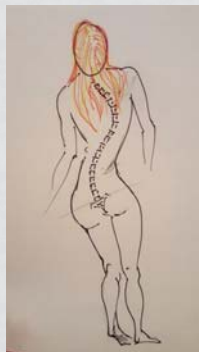
- Pain prevents patient from walking more than 1K. When pain flared, <500 meters. Increases up/down stairs.
- Sitting prolonged at work >1 hour causes R hip numbness/burning anteriorly.
- Unable to stand more than 10 minutes or lift objects overhead at work.
- Social life and travel create extra pain (mall with friends etc.)
- **Everyday pain:** R anterior hip pain and L sciatica/gluteal pain

## Functional Tests

- SLS squat: knee “wobble” bilaterally but no excess valgus moment or femoral IR
- **Impression:** Idiopathic scoliosis progression with resultant L Lumbar Spine failure & L LE weakness

## Evaluation Findings

- **Gait:** R hip pain, insufficient knee flexion at load response
- **Standing:** R Scapula inferior angle winging, R thoracic rib hump until L1. Curve then reverses to L lumbar rotation
- **Cervical rotation:** R rotation discomfort but range full. All other AROM painfree
- **Shoulder AROM:** R flexion 90% of L (compensated). Others full
- **Thoracic AROM SB:** R restricted. L FULL
- **Thoracic AROM Rot:** decreased L, but discomfort R
- **Non Weight-bearing Landmarks:** R ASIS superior, R malleolus superior, R PSIS inferior (posterior rotation)



## Problem List

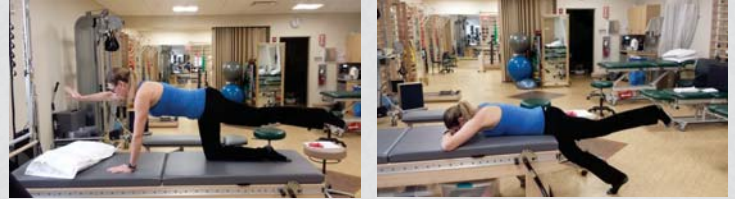
- Congenital scoliosis compensated/progressed
- Decreased L hip strength and affected gait/stairs
- Limited gait distance for commute to work and social activities

## Plan of Attack

- Decrease influence of continued muscle shortening on the curves progression
- Improve generalized thoracic spine, lumbo-pelvic and rib cage joint mobility
- Lengthen shortened muscles, strengthen weakened muscles, core stabilization, hip flexibility, postural stabilization
- **PT goals:** 5/5 gluteus med L, up down stairs without pain, walk in mall with friends 2hours without pain. Design/provide final home exercise program to patient that is counter to the curves progression.

## TREATMENT

- Once patient demonstrated decreased pain with walking and increased exercise tolerance at 3 visits, introduced hip strengthening and postural stabilization... quadruped alternate UE LE and hip Ext off table. And GG 3D stretch series



## FIRST COURSE OF ACTION

- **Soft tissue mobilization** to lengthen the muscles on the short/concave side.
- **Joint mobilization** to improve mobility of the facets in the opposite direction of the curve
- **Therapeutic exercise and home exercises** for the purpose of moving the body in the opposite direction of each curve and strengthening the muscles on the convex side. **Re-TRAIN the Brain!!!**

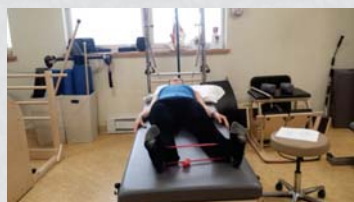## TREATMENT

- Slowly introduced R hip flexor strengthening, sidesteps and upper body postural stabilization. **Patient and her mother noticed decreased visible rib hump!**



## TREATMENT

- **Initial treatments** emphasized STM to spinal rotators (L thoracic, R lumbar), QL and Lumbo Dorsal fascia, R hip flexor group proximally and joint mobilizations to the rib cage and thoracic spine away from the curve.
- **Therapeutic exercise** encouraged transverse abdominus re-education, active sidelying spinal de-rotation, and gluteus medius strengthening
- **\*Patient reports less fatigue in L leg when going up \ down stairs and no R anterior hip pain after walking 5 blocks!**



## RESULTS

**“Thank you so much! You changed my life.”**

- With anyone we see who has a concomitant idiopathic scoliosis, it is important to take into consideration the effects the progression of the curve may have on the ailment they are presenting with that day.
- In the case presented, the so-called “unwinding” of her curves’ progression was the key to improving her muscle function so that she may return to full function and enjoyment of life activities.



## RELEVANT ANATOMY

### Trunk Stabilizers

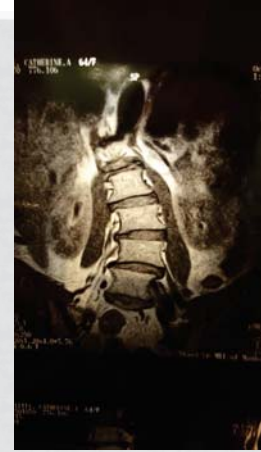- Abdominals
  - Obliques
  - Paraspinals
  - Latissimus Dorsi
- Deep rotators (spinal stabilizers)
  - Multifidii

### Pelvis Stabilizers

- Gluteus Medius
- Gluteus Maximus
- Quadratus Lumborum

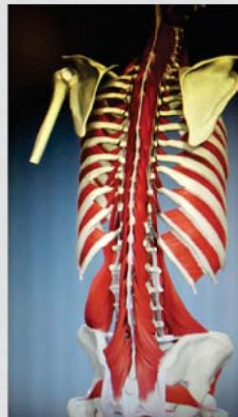Demystifying Scoliosis Feb 18, 2017  
Property of Christine Lynders, Not to be distributed without permission

## ILIOPSOAS SHORTENS IPSILATERALLY



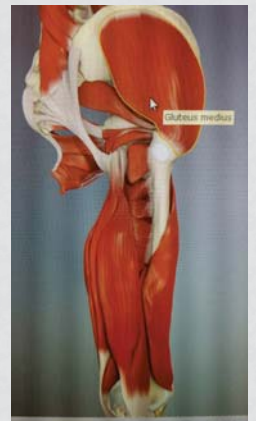
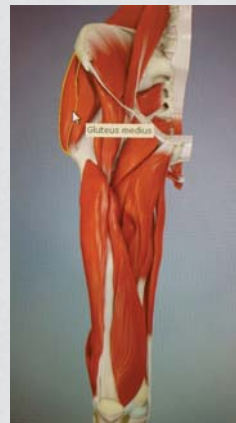## WHAT MUSCLES HAVE COMPENSATED?

- **Multifidus** – one of the most powerful spinal stabilizers. They support the spine! Studies have shown that these mm get activated BEFORE you even move to reach. When your brain says, "I want to reach for that," they should fire.



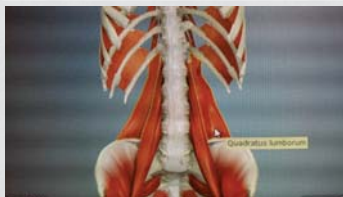## WHAT MUSCLES HAVE COMPENSATED?

- **Gluteus Medius-**

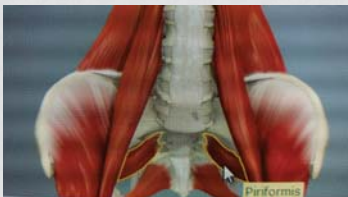


Demystifying Scoliosis Feb 18, 2017  
Property of Christine Lynders, Not to be distributed without permission

## WHAT MUSCLES HAVE COMPENSATED?

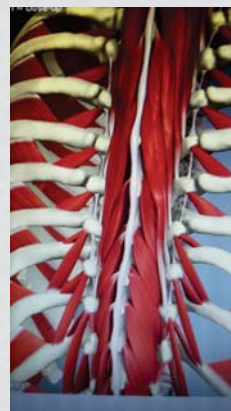

- **Quadratus Lumborum** – iliac crest, IL ligament, 12<sup>th</sup> rib, TPs LS
- **Iliopsoas-**
  - Major: Vertebral bodies/TPs and IV discs T12-L4 to lesser trochanter
  - Minor: Vertebral bodies T12, L1 to lesser trochanter
- **Piriformis-** Attaches to the front of the sacrum so if pelvis is sidebent and femur IR'd....sciatica??



Demystifying Scoliosis Feb 18, 2017  
Property of Christine Lynders, Not to be distributed without permission

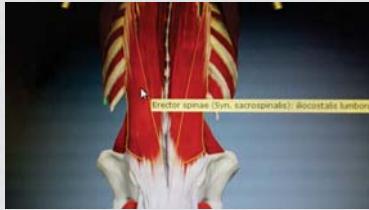## THORACIC MULTIFIDUS



- **Thoracic Multifidus**
- **Levator Costarum**

## THORACO-LUMBAR MUSCULATURE

- **Iliocostalis Lumborum**  
– responsible for back extension. Provides resistance with forward flexion and contracts to bring the body back up to erect. This muscle facilitates good posture!!!
- **Spinalis=>Longissimus =>Iliocostalis**

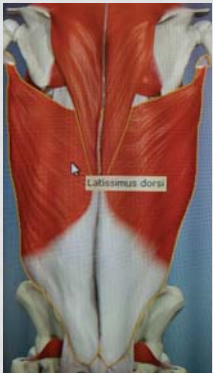


## WHAT CAN GO WRONG?

- **From The GROUND UP...**
- **Foot** – Pronation/supination to lengthen or shorten the limb AKA level the pelvis
- **Knee** – if excessive pronation, get increased tibial IR, potential for knee pain/valgus tendency (Ex. Stef)
- **Hip** – If above occurs, get increased hip IR at LR, large eccentric load over and over on gluteus medius → leads to gluteal pain, bursitis, fatigue → eventual hip drop over time → **Pelvic drop** → **Lumbar** sidebending = lumbar compression → disc herniation, sciatica, low back pain!

## WHAT CAN GO WRONG??

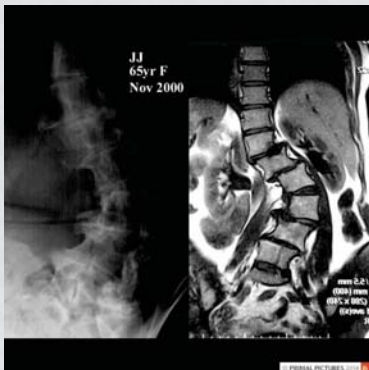
- **From the TOP DOWN...**
- **Cervical** – sidebends to keep head/eyes level. Levator scapula pain, cervical compression, headaches
- **Thoracic** – Shortened muscles on concavity, lengthened on convexity. Shoulder pain, pec shortening (**Stefanie Ex.**)
- **Ribs** – Ribs follow the TS so can get decreased respiratory ability, intercostal pain, limited shoulder ROM overhead
- **Pelvis** – depending on whether C or S curve, get shortened QL/lengthened opposite, pelvic obliquity in frontal plane as a result and eventually in sagittal plane as the body attempts to level the limbs



- **Latissimus Dorsi**- SPs T6-S5 to humerus, Thoraco- Dorsal fascia

Demystifying Scoliosis Feb 18, 2017  
Property of Christine Lynders, Not to be distributed without permission

## HOW SCOLIOSIS CAN AFFECT NECK AND LOW BACK PAIN.....RADICULOPATHY??



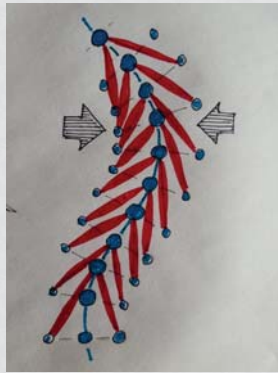
Demystifying Scoliosis Feb 18, 2017  
Property of Christine Lynders, Not to be distributed without permission

## WHO IS WALKING INTO YOUR CLINIC?

- **SR** - "shoulder pain", dx labral tear, severe knee pain post 2-3 surgeries. (was Utrap/periscap pain from scoliosis!!!)
- **EH** - Low back pain from standing at work, lumbar radiculopathy from changing to a standing desk at school
- **LB** – hip pain, sciatica opposite side, R neck pain
- **EF**– back pain, neck pain, thoracic pain "constant" at desk job
- **AH** – back pain, debilitating SI pain, sciatica
- **Phyllis** – hip pain to walk around city for errands, inability to stand on one leg 2/2 gluteal insufficiency
- **V 15 y/o** L low back pain, R TS mm spasm and right neck pain progressed 5 degrees in 6 months

## HERE'S WHAT I SEE WHEN I LOOK AT A SCOLIOSIS

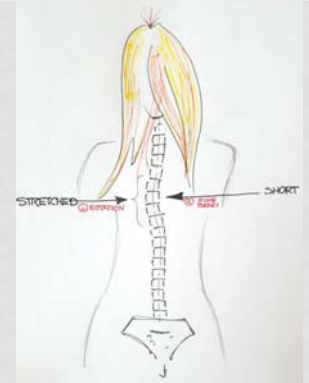
- This is a Right thoracic curve = the spine is rotated right creating a visible rib hump and is sidebent left (type I mechanics neutral)



Demystifying Scoliosis Feb 18, 2017  
Property of Christine Lynders, Not to be distributed without permission

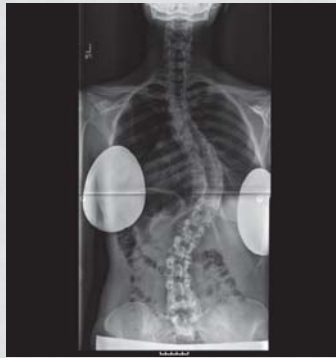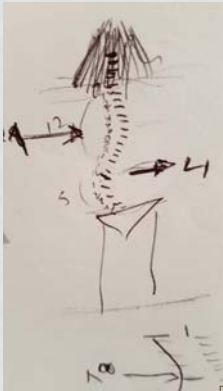## DRAW IT

- If I drew the above, here's what it would look like
- Thoracic rotated L, SB R ending at T8
- **What muscles are we targeting in the curve?**
- RIGHT TS multifidii to loosen, L thoracic paravertebrals and multifidii to strengthen



Demystifying Scoliosis Feb 18, 2017  
Property of Christine Lynders, Not to be distributed without permission

## IDENTIFY THE CURVE AND DETERMINE WHICH MUSCLES NEED TO BE LENGTHENED/STRENGTHENED

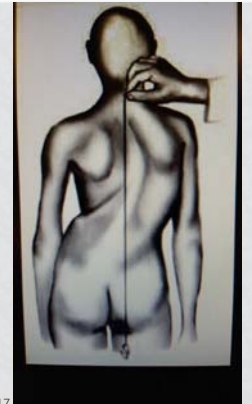

Demystifying Scoliosis Feb 18, 2017  
Property of Christine Lynders, Not to be distributed without permission

## EVALUATIVE/DIAGNOSTIC TOOLS

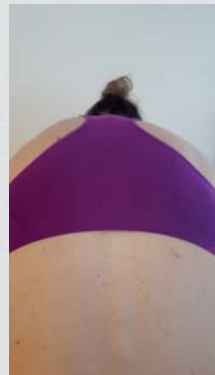
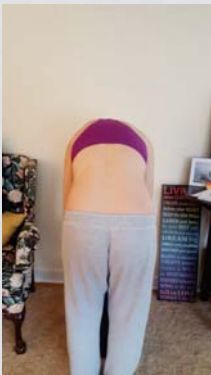
Scolimeter  
Tilt meter APP and phone holder  
Plumbline (to see sacral/pelvic shift)



Demystifying Scoliosis Feb 18, 2017  
Property of Christine Lynders, Not to be distributed without permission

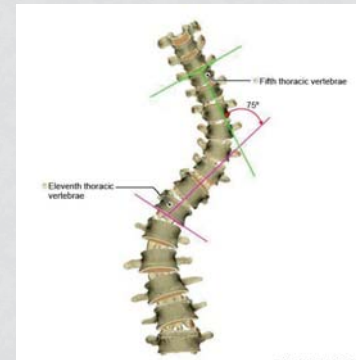## IDENTIFY THE CURVE



Demystifying Scoliosis Feb 18, 2017  
Property of Christine Lynders, Not to be distributed without permission

## OTHER DIAGNOSTICS

- **FF test/Adam's test** (look for the rotation/rib hump on the side of the convexity)
- **Xray** (gold standard)
- **Cobb angle > 10 degrees**
- **Scolimeter > 5-7 degrees**



Demystifying Scoliosis Feb 18, 2017  
Property of Christine Lynders, Not to be distributed without permission

## EVALUATION

**History:** Previous injuries

**Gait:** look for toe-out, trunk lean, transverse plane rotation pelvis, arm swing

**SLS squat:** knee valgus, hip drop etc.

**Standing** - Note iliac crest levels, shoulders, curve, feet

**Forward flexion-** Note rib hump, curve reversal, apparent leg length discrepancy; March test, Sacral SB test

**Seated-** Note curve, Available trunk rotation

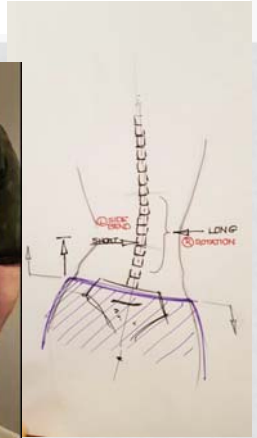
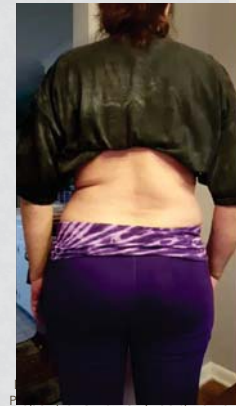
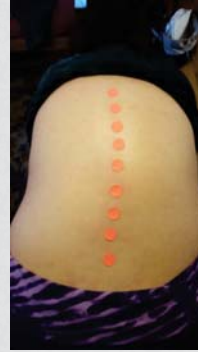**Supine-** Pelvic landmarks, LE flexibility, TA coordination, Thomas test, hip IR/ER

**Sidelying-** Hip abductor strength

**Prone-** Segmental mobility, multifidus firing patterns, abnormal muscle tone, glut max, Hip IR/ER

## IDENTIFY THE CURVE

### Forward Flexion



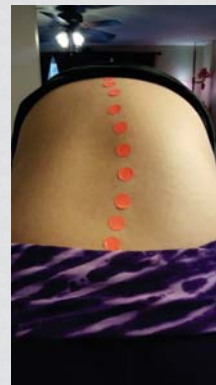be distributed without permission

## ADULT WITH PROGRESSIVE IDIOPATHIC SCOLIOSIS & LOW BACK PAIN: CASE STUDY

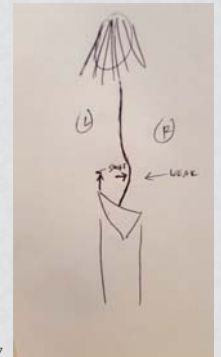- **History:** Lower "S" scoliosis found in grade school. C/o LBP and L knee pain starting at 28 y/o. Thought she had Lyme. Saw Chiro which helped somewhat but pain pattern did not change. Also lost wt to 155 lbs and currently 205 lbs with no change in pain. L hip pain that "pops out of place."
- **PMHx:** Anxiety, fall in early 20s down stairs on tailbone and 3x MVA without change in LBP.
- **Imaging:** xrays at 37 y/o reported moderate lumbar arthritis and "all cushion worn between vertebrae" from so many years of not knowing what was going on.

Demystifying Scoliosis Feb 18, 2017  
Property of Christine Lynders, Not to be distributed without permission

## IDENTIFY THE CURVE



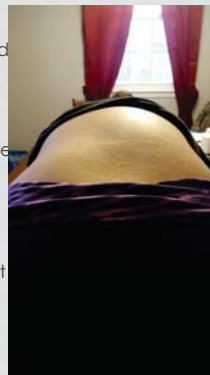### Draw the Curve to Visualize



Demystifying Scoliosis Feb 18, 2017  
Property of Christine Lynders, Not to be distributed without permission

## FUNCTIONAL LIMITATIONS

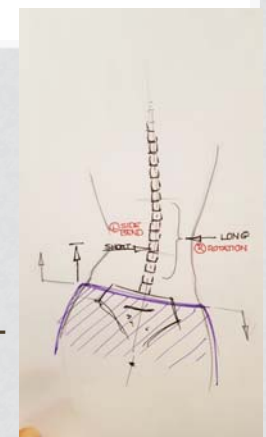
- **Pain** in sitting, feels "not aligned". If sitting prolonged and shifts, gets sciatic pain into either leg.
- Central LBP from sacrum up to low thoracic region and goes outward across low back.
- **Cannot :**
  - sit cross-legged any longer
  - come UPSTAIRS carrying anything because of severe LBP?!
  - Walk in Costco because pain is severe walking out
  - Work as a bus driver any longer-could not take the "bounce"
- Car sitting- gets out bent and takes time to get straight again (NEVER THOUGHT ANYTHING OF IT)
- Pain comes and goes and never goes away.
- **Her GOAL-** she wants to get back to being able to function more towards when she was younger and dec pain with ADLs!



Demystifying Scoliosis Feb 18, 2017  
Property of Christine Lynders, Not to be distributed without permission

## CURRENT HYPOTHESIS

- What would be **shortened**?
  - L Quadratus Lumborum
  - L lumbar multifidus
  - ? L lats via lumbodorsal fascia
- What might be **tender** to palpation?
- What would be **weakened/long**?
  - R lumbar paraspinals
- What would be **inhibited**?
  - L glute medius from functional LLD
- What might we see on exam **kinetic-wise**?
  - SLS with hip drop L
  - Toed-out L



Demystifying Scoliosis Feb 18, 2017  
Property of Christine Lynders, Not to be distributed without permission

## EVALUATION- GAIT AND FUNCTIONAL MOVEMENTS

Good rear view R



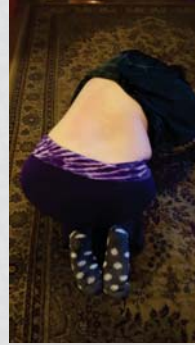
Functional SLS balance and squat



Demystifying Scoliosis Feb 18, 2017  
Property of Christine Lynders, Not to be distributed without permission

**TREATMENT:** 1. STM TO L MULTIFIDUS, QL, SUPERIOR MFR TO RIBS  
2. TA MARCH AND CORRECT PELVIS WHILE WALKING UP STAIRS ETC.

Curve stretching



Demystifying Scoliosis Feb 18, 2017  
Property of Christine Lynders, Not to be distributed without permission

## SLS SQUAT

Note LS Sb and R transverse plane rotation



With pelvis corrected in transverse plane



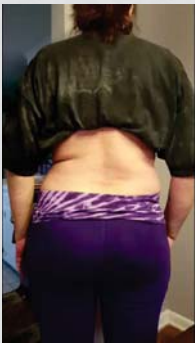Demystifying Scoliosis Feb 18, 2017  
Property of Christine Lynders, Not to be distributed without permission

## RESULTS AFTER INITIAL EVALUATION AND TREATMENT

- Able to SB further without pain immediately
- Woke up without LBP for the first time in decades
- After 4 days HEP, was able to sit cross-legged again

Demystifying Scoliosis Feb 18, 2017  
Property of Christine Lynders, Not to be distributed without permission

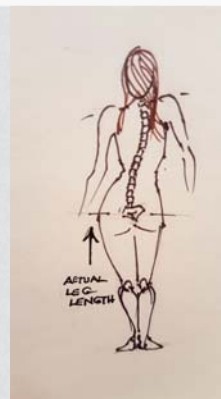## EVALUATION- AROM



- Note limited segmental mobility R and increased ease with SB left
- L crest UP
- MMT; L glute med 3+/5, R 4+/5
- Supine: pelvis level, mall level, extended lordosis on the L
- Palpation: TTP B SI, glutes, L4 and L5. L multifidii, QL (good sore); R side "Sore".
- Prone multifidus firing: Spinal twist to the L with leg lift/R ASIS comes up

Demystifying Scoliosis Feb 18, 2017  
Property of Christine Lynders, Not to be distributed without permission

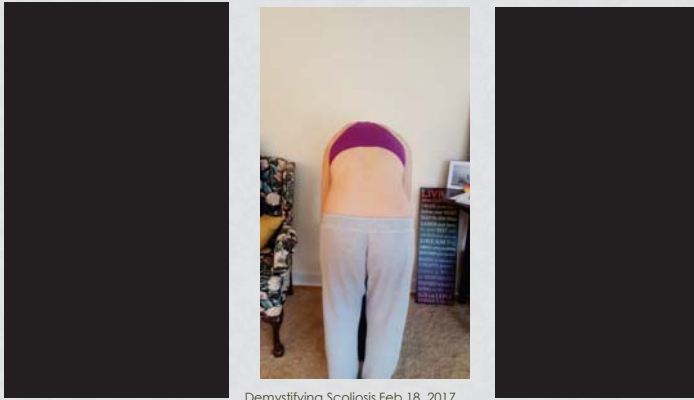
## 59 Y/O FEMALE LOW BACK PAIN, RADICULOPATHY



- **Curve TS-** R rib hump (TS convex R-rot R)
- **Curve LS-** LS SB R/rot L?
- c/o L hip pain wraps around buttock to ITB.
- **SLS L-**transverse pelvic rotation and valgus at knee
- Long left leg

Demystifying Scoliosis Feb 18, 2017  
Property of Christine Lynders, Not to be distributed without permission

## SELF 3D CORRECTION



Demystifying Scoliosis Feb 18, 2017  
Property of Christine Lynders, Not to be distributed without permission

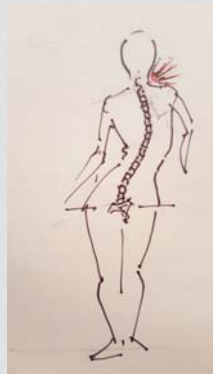
## REGISTERED NURSE

- **Chief c/o** R sided "shoulder" pain (points to R upper trapezius and levator scapula) x 1.5 years with work, tennis and to reach OH especially at R shoulder blade region
- **Medical Diagnosis:** R labral tear
- **Exam Findings:** C curve scoliosis SB R/ rot L starting at T4, R scapular winging and anterior tilt, poor posture with B humeral IR (excessive) as well as increased TS kyphosis. **\*\*\*Severe sensitivity to palpation thoracic3-7**
- **Treatment:** Manual therapy, scapular strengthening, postural & core strengthening, WB functional strengthening and awareness education

Demystifying Scoliosis Feb 18, 2017  
Property of Christine Lynders, Not to be distributed without permission

## PAIN IN THE NECK?!

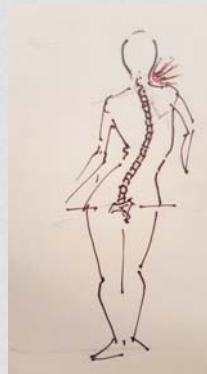- In order to keep the eyes level and facing forward
- Think!! Levator scapulae role, Scalenes.



Demystifying Scoliosis Feb 18, 2017  
Property of Christine Lynders, Not to be distributed without permission

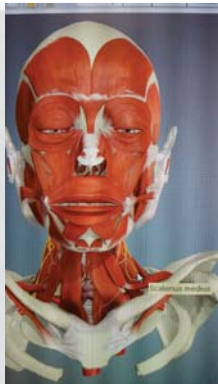
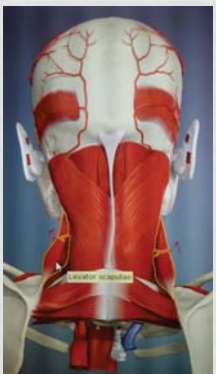## INTERIOR DESIGNER

- R sided neck pain on side of convexity
- Band exercises to stabilize scapula on rib cage, cervical strengthening exercises, scoliosis specific exercises



Demystifying Scoliosis Feb 18, 2017  
Property of Christine Lynders, Not to be distributed without permission

## RELEVANT NECK MUSCULATURE



- **Levator scapulae-** TP's C1, C2, posterior tubercle C3, C4 → superior angle & medial border scapula
- **Scalenes-** Posterior tubercles cervical 2-7 → 1<sup>st</sup> & 2<sup>nd</sup> rib

Demystifying Scoliosis Feb 18, 2017  
Property of Christine Lynders, Not to be distributed without permission

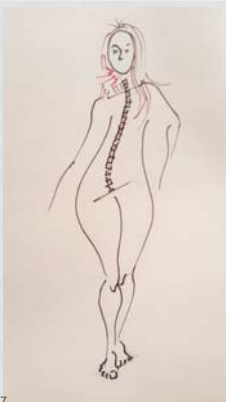## QUICK FIXES TREATMENT

- Ex. PT student with S curve. Watched gait. Toed out unilaterally.
- Watched SLS squat. Knee valgus significant and poor balance
- Correction- Turn foot straight and try again. 85% improved with dec trunk lean and dec knee valgus/fem IR. **→SUCCESS!!!!**

Demystifying Scoliosis Feb 18, 2017  
Property of Christine Lynders, Not to be distributed without permission

## THINK KINETIC CHAIN INFLUENCES

- **Toed out-** turn foot straight to fire the glutes
- **Valgus Knee:** Fire glutes to control.



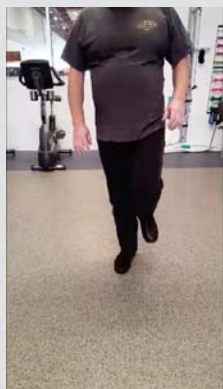
Demystifying Scoliosis Feb 18, 2017  
Property of Christine Lynders, Not to be distributed without permission

## ADOLESCENT PROGRESSIVE SCOLIOSIS

- 15 y/o male with LBP at thoraco-lumbar junction L>R with sitting prolonged, standing with c/o "spasm" and L foot numbness to lie down.
- **Gait:** Lands hard on R
- **SLS balance** was "off" R & **SLS squat R** knee dives into valgus with c/o knee pain
- **AROM LS:** In extension, hinges at T12-L1
- **SLR:** R 35, L45
- **MMT hip abd** R 4/5, L 5/5
- **Poor posture!!!** Showed him a picture and he was able to correct after THAT!!!
- Found on Xray 10 degree curve. (LS L Sb AKA convex R)
- Created movement pattern dysfunction with rows and retractions. With rows, demo SBing of the spine but did not know why.

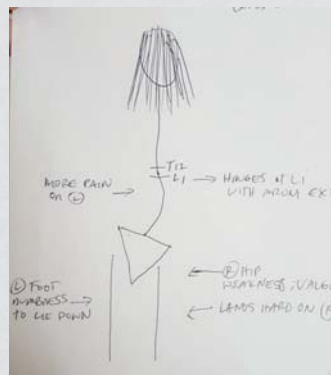
Demystifying Scoliosis Feb 18, 2017  
Property of Christine Lynders, Not to be distributed without permission

## NORMAL SINGLE LIMB BALANCE



- **Post-op** spinal fusion 2 levels
- **Pre-op** c/o severe R LE radiculopathy

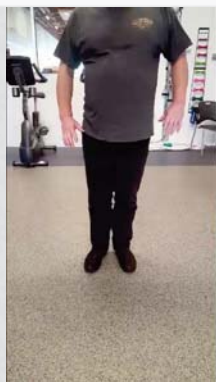Demystifying Scoliosis Feb 18, 2017  
Property of Christine Lynders, Not to be distributed without permission



- HS stretch
- Hip abd bands
- Ball bridges
- Bosus SLS squats
- TA series
- Prone alt LE series
- Quad alt UE LE (ball)
- Side eccentric abd
- Ball abs prone
- Scapula retrax series
- Towel under R IT
- Side Stretch over pillow
- Seated correction with band twist (plinth and ball)

Demystifying Scoliosis Feb 18, 2017  
Property of Christine Lynders, Not to be distributed without permission

## ABNORMAL SINGLE LIMB BALANCE

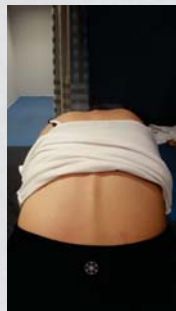

Demystifying Scoliosis Feb 18, 2017  
Property of Christine Lynders, Not to be distributed without permission

## CASE STUDY: ADOLESCENT

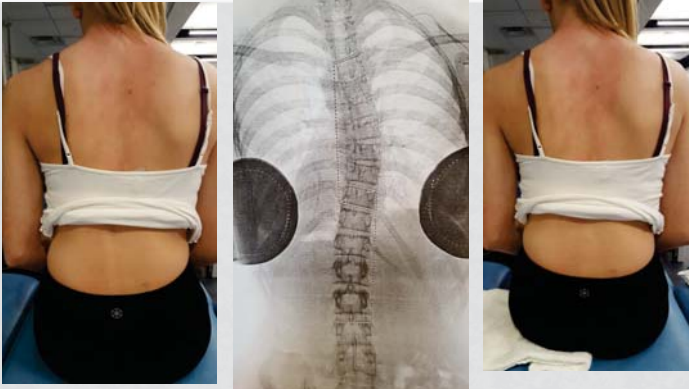
Curve increased from 28 degrees to 33 degrees in 8 months.

Only wearing night brace, Providence



Demystifying Scoliosis Feb 18, 2017  
Property of Christine Lynders, Not to be distributed without permission


## SMALL TIPS CAN MAKE A HUGE IMPACT!!!



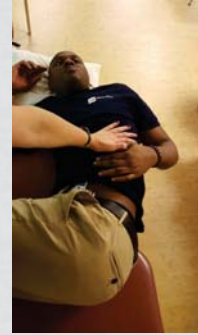Demystifying Scoliosis Feb 18, 2017  
Property of Christine Lynders. Not to be distributed without permission

## MANUAL THERAPY TECHNIQUES

PA Ribcage



TS sideglides and SL CR TS rotation

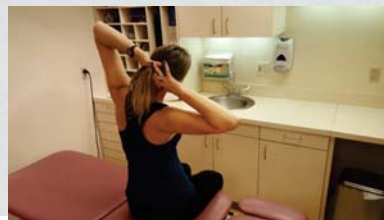
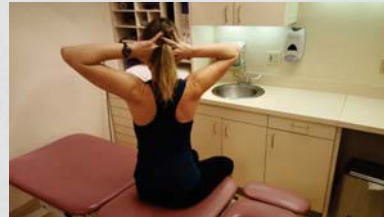
## DAILY SELF-CARE PLAN

- **Re-educate** appropriate muscles by strengthening and active lengthening 3-dimensionally; Focus on self-correction!!!
- **Re-train** and facilitate the nervous system to acknowledge the new position as "normal"
- **HEP's** must be-
  - Specific
  - Individualized
  - Learned (repetition)

## MANUAL THERAPY TECHNIQUES

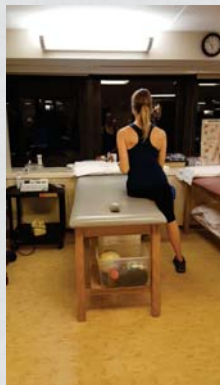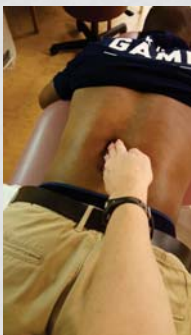Seated TS rotation CR



## MANUAL THERAPY TECHNIQUES

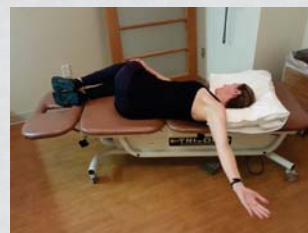SL stretch over table with MFR to thoracolumbar fascia/QL (normalize tissue tension to allow for more normal joint mobility)

Prone in R SB STM multifidus TS



## PASSIVE LENGTHENING EXERCISES

Trunk Rotation away from the curve



Spine Corrector or Foam Roll for SB away from the curve





## PASSIVE LENGTHENING EXERCISES

Right Sidebend Stretch



Left Rotation Stretch

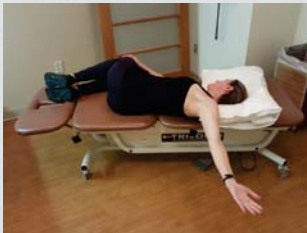
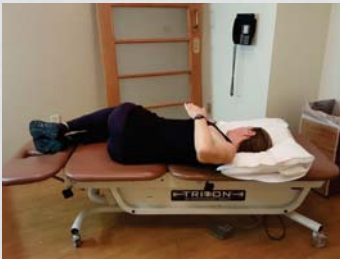
Active Left Rotation (Repetitive)  
with Fixed Right Sidebend




## RE-EDUCATION FOR HEP

Active TS de-Rotations to the  
Left



## RE-EDUCATION FOR HEP

Resisted Right Sidebend



## RE-EDUCATION FOR HEP



Active Left Rotation (Repetitive)



Active Right Sidebend  
(repetitive)



## RE-EDUCATION FOR HEP



## RE-EDUCATION FOR HEP

Strengthening Left QL/ Lumbar



- **Sidebend right with active left rotation**



## 2-3D SELF-CORRECTIVE EX

- **Anti-scoliosis active exercise regimen to prevent further curve progression, lengthen and re-educate muscles on the either side of the curve**

- **Left thoracic rotation**



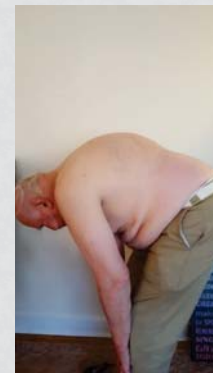## FINAL HOME PROGRAM

- **1<sup>st</sup>** learning (mirror, 1D 2D, can they feel their trunk is more corrected than before? Take a video)
- **2<sup>nd</sup>** breathing, remove visual assist
- **3<sup>rd</sup>** endurance in corrected position
- **4<sup>th</sup>** control. Keep it simple at first to enable "correct" correction

Demystifying Scoliosis Feb 18, 2017  
Property of Christine Lynders, Not to be distributed without permission

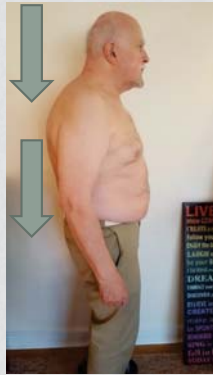## WHAT DO YOU DO WITH THIS??

- **Active right sidebend**

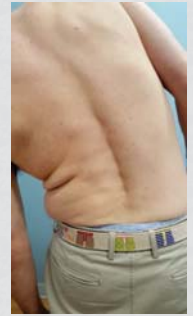
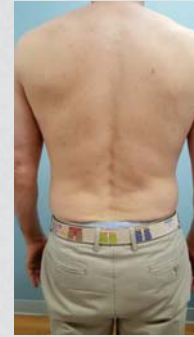
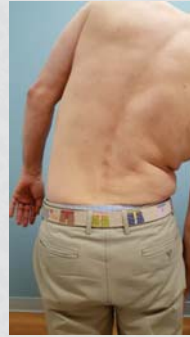Demystifying Scoliosis Feb 18, 2017  
Property of Christine Lynders, Not to be distributed without permission

## SIT UP STRAIGHT!?!..OR ELSE...

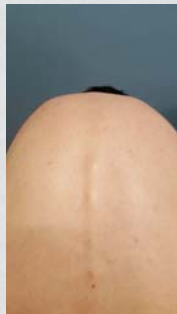
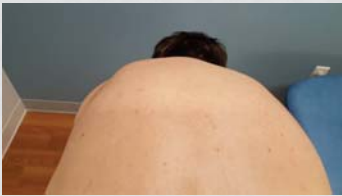
Demystifying Scoliosis Feb 18, 2017  
Property of Christine Lynders, Not to be distributed without permission



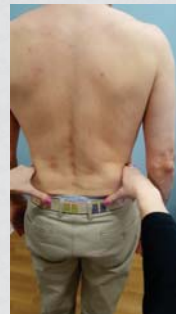Demystifying Scoliosis Feb 18, 2017  
Property of Christine Lynders, Not to be distributed without permission

## CASE STUDY

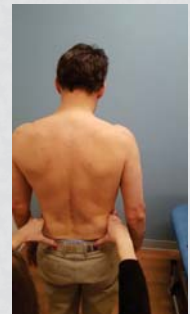

Demystifying Scoliosis Feb 18, 2017  
Property of Christine Lynders, Not to be distributed without permission

With lift



Without lift in left shoe



Demystifying Scoliosis Feb 18, 2017  
Property of Christine Lynders, Not to be distributed without permission

- 45 y/o male presented with R shoulder pain to push off wall in squash, tuck shirt in and night pain (worst)
- L handed squash player
- Findings: shoulders "unevel" (R significantly lower)
  - Depression R scapular muscle area
  - MMT scapular rotators less than 3/5 R
  - H/o scoliosis where his foot orthotic was built up by a lift to correct

Demystifying Scoliosis Feb 18, 2017  
Property of Christine Lynders, Not to be distributed without permission

## CONCLUSION

- **STEP #1:** Decrease influence of shortened muscles multifidus, QL (release the problem area first, making it possible to move in the right direction)
- **STEP #2:** Strengthen the weak side (might be sore...hasn't worked in years!)
- **STEP #3:** Re-train the Brain!!!
- Side note: Use caution if stretching QL "knot", and no relief, try strengthening it!!

Demystifying Scoliosis Feb 18, 2017  
Property of Christine Lynders, Not to be distributed without permission

## PERSPECTIVE ON KIDS?

- Encourage them to carry backpacks in the center ..not one side or the other, which would give the spine a constant stimulus to react one-directionally
- If you give yourself an abnormal stimulus with backpack or fall off bike and limp a little, or hurt shoulder and holding it tucked to guard it, giving your nervous system abnormal stimulus during the growth spurt
- Sports? Vball, tennis, etc. One-sided sports. Strengthen the other side to regain balance

THANK YOU!!

CLYNDERSRUN@GMAIL.COM



Demystifying Scoliosis Feb 18, 2017  
Property of Christine Lynders, Not to  
be distributed without permission

## REFERENCES

1. Fortin C, Feldman D, Chretien F, Gravel D, Gauthier F, Labelle H. Reliability of a quantitative clinical posture assessment tool among persons with idiopathic scoliosis. *Physiotherapy* 98 (2012); 64-75
2. Romano M, Negrini A, Parzini S, Tavernara M, Zaina F, Donzelli S, Negrini S. SEAS (Scientific Exercises Approach to Scoliosis): a modern and effective evidence based approach to physiotherapeutic specific scoliosis exercises. *Scoliosis* (2015) 10:3
3. Mendoza-Lattes SA MD, Pugely A, Gnanapradeep G MD, Nash R, Gao Y. Foraminal dimensions in adult patients with scoliosis and radiculopathy. *Spine: Affiliated Society Meeting Abstracts* (2011): 133-134 E Poster #234
4. Azevedo DC, Van Dillen LR, De Oliveira Santos H, Oliveira DR, Ferreira PH, Oliveira Pena Costa L. Protocol of a Randomized Controlled Trial Versus General Exercise for Chronic Low Back Pain: Movement System Impairment-Based Classification. *PHYS THER* published ahead of print April 30, 2015. doi:10.2522/ptj.20140555
5. Negrini A, Parzini S, Negrini M, Romano M, Atanasio S, Zaina F and Negrini S. Adult Scoliosis can be reduced through specific SEAS exercises: A Case Report. *Scoliosis* 2008, 3:20 doi:10.1186/1748-7161-3-20
6. LeBauer A, Brfalk R and Stowe K. The Effect of Myofascial Release (MFR) on an Adult with Idiopathic Scoliosis. *Journal of Bodywork and Movement Therapies*, 2008-10-01Z, Volume 12, Issue 4, pages 356-363.
7. Kreiner DS, Hwang SW, Easa JE, Resnick DK, Baisden JL, Cho CH, et al. An evidence-based clinical guideline for the diagnosis and treatment of lumbar disc herniation with radiculopathy. *The Spine Journal* 2014;14(1):180-191.
8. Manuel D Rigo and Theodoros B Grivas. "Rehabilitation schools for scoliosis" thematic series: describing the methods and results. *Scoliosis* 2010, 5:27 doi:10.1186/1748-7161-5-27
9. Kotwal S, Pumberger M MD, Hughes A MD, Girardi F MD. Degenerative scoliosis: A review. *HSS Journal* (2011) Oct;7(3): 257-264.
10. Amendt, L. E., Ause-Ellias, K. L., Eybers, J. L., Wadsworth, C. T., Nielsen, D. H., & Weinstein, S. L. (1990). Validity and Reliability Testing of the Scoliometer. *Physical Therapy*, 70(2), 108-117. Accessed October 30, 2016. Retrieved from <http://ptjournal.apta.org/content/70/2/108>

Demystifying Scoliosis Feb 18, 2017  
Property of Christine Lynders, Not to  
be distributed without permission

## ILLUSTRATIONS BY...



Demystifying Scoliosis Feb 18, 2017  
Property of Christine Lynders, Not to  
be distributed without permission